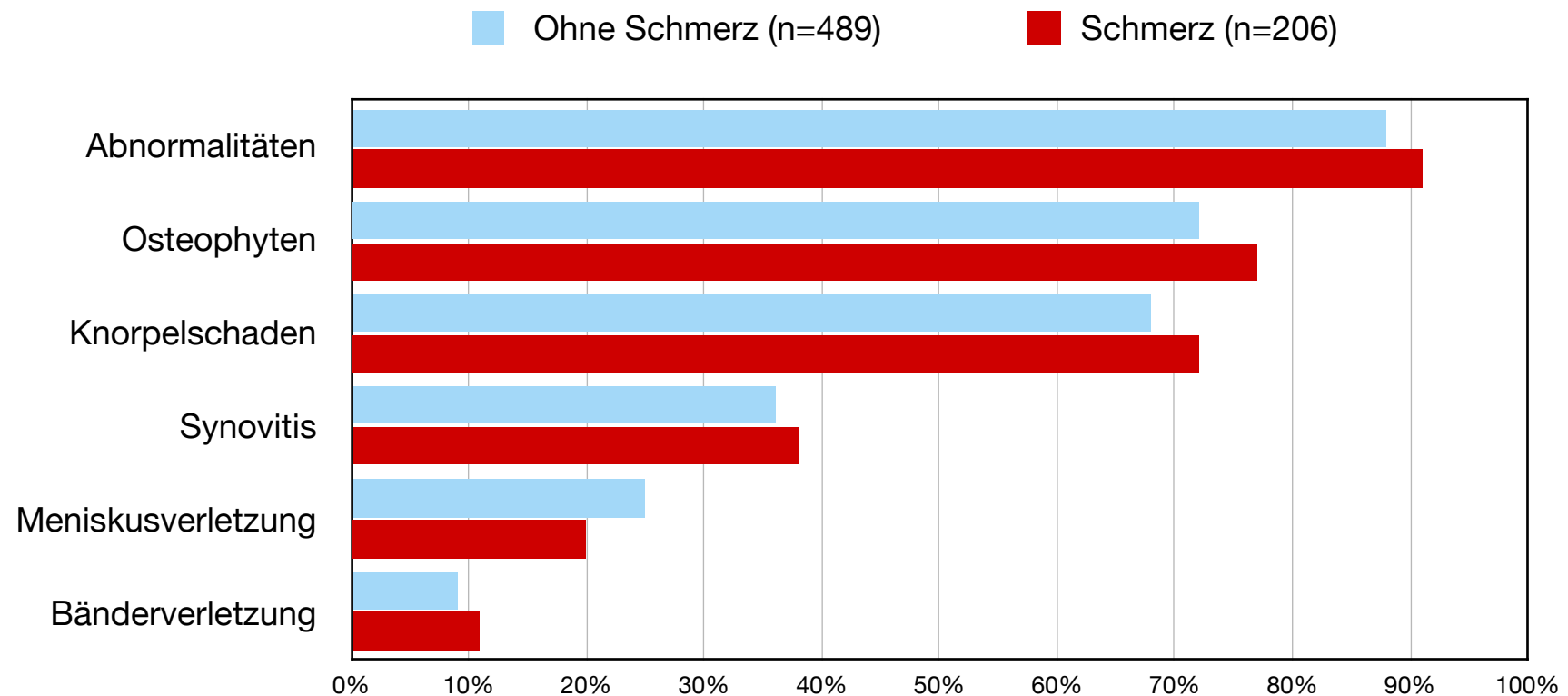


MRT-Befunde des Kniegelenks bei Menschen ohne Arthrose

Teilnehmer 51-89 Jahre (n=710)



Synovitis = Entzündung der Gelenkschleimhaut; Osteophyten = Knochenneubildungen

A. Guermazi, J. Niu, D. Hayashi, F.W. Roemer, M. Englund, T. Neogi, P. Aliabadi, C.E. McLennan, and D.T. Felson. (2012). Prevalence of abnormalities in knees detected by MRI in adults without knee osteoarthritis: population based observational study (Framingham Osteoarthritis Study). The BMJ, 345, e5339. doi: <https://doi.org/10.1136/bmj.e5339>